


**GET HELP FROM
CMS HERE**



Heparin-induced thrombocytopenia

DB Brieger, KH Mak, K Kottke-Marchant, and EJ Topol
J. Am. Coll. Cardiol. 1998;31;1449-1459

This information is current as of February 10, 2012

The online version of this article, along with updated information and services, is located on the World Wide Web at:
<http://content.onlinejacc.org>

JACC

JOURNAL of the AMERICAN COLLEGE of CARDIOLOGY



REVIEW ARTICLE

Heparin-Induced Thrombocytopenia

DAVID B. BRIEGER, MB, BS, PhD, KOON-HOU MAK, MB, BS,
KANDICE KOTTKE-MARCHANT, MD, PhD, ERIC J. TOPOL, MD, FACC

Cleveland, Ohio

Heparin-induced thrombocytopenia (HIT) is a potentially serious complication of heparin therapy and is being encountered more frequently in patients with cardiovascular disease as use of anticoagulant therapy becomes more widespread. Our understanding of the pathophysiology of this immune-mediated condition has improved in recent years, with heparin-platelet factor 4 complex as the culprit antigen in most patients. New sensitive laboratory assays for the pathogenic antibody are now available and should permit an earlier, more reliable diagnosis, but their optimal application remains to be defined. For patients in whom HIT is diagnosed, immediate discontinuation of heparin infusions

and elimination of heparin from all flushes and ports are mandatory. Further management of patients with HIT is problematic at present, as there are no readily available alternative anticoagulant agents in the United States with proven efficacy in acute coronary disease. The direct thrombin inhibitors appear to be the most promising alternatives to heparin, when continued use of heparin is contraindicated, and the results of several multicenter trials evaluating their application in patients with HIT are awaited.

(J Am Coll Cardiol 1998;31:1449-59)

©1998 by the American College of Cardiology

Since it was first used to prevent venous thrombosis in surgical patients in 1937, heparin has been the anticoagulant therapy of choice for the prevention and early management of arterial and venous thromboembolic disease (1). Heparin plays a major role in cardiovascular therapy; it is the routine anticoagulant agent used in percutaneous transluminal coronary angioplasty and coronary artery bypass graft surgery and has confirmed value in the management of patients with unstable angina (2,3) and as adjunctive therapy in patients receiving thrombolysis after myocardial infarction (4). Because of the vast clinical experience with heparin, physicians are generally well aware of most of the practical limitations associated with its use, including the potential for bleeding and interpatient variability in anticoagulant response after administration (5). The focus of this report, however, is one of the potentially most devastating but least well recognized complications of heparin therapy—its propensity to cause thrombocytopenia with associated thrombosis. With the more frequent use of heparin in recent years, the prevalence of this potentially catastrophic complication has prominently increased (Fig. 1).

Frequency of Thrombocytopenia

Approximately 10% to 20% of patients will develop a transient mild thrombocytopenia after 1 to 4 days of heparin therapy. The platelet count rarely goes below 100,000/ μ l, often becomes normal despite further heparin administration and is generally without clinical sequelae. This benign form of heparin-induced thrombocytopenia (HIT), attributed to a direct interaction between administered heparin and circulating platelets, is classified as HIT type I (6) (Table 1).

The more sinister form of HIT generally develops after 5 to 10 days (mean 7 to 8) of heparin therapy. This form is antibody mediated, can be associated with potentially devastating thromboembolic sequelae and is classified as HIT type II and is the topic of this report. A recent prospective, randomized study of 665 patients receiving either subcutaneous unfractionated or low molecular weight (LMW) heparin for thromboprophylaxis after hip surgery reported a frequency rate of HIT of 2.7% in patients receiving unfractionated heparin and 0% in patients receiving LMW heparin. HIT was defined as a decrease in the platelet count $<150,000/\mu$ l occurring at least 5 days after beginning heparin therapy, accompanied by heparin-dependent antiplatelet antibodies detected by the sensitive 14 C-serotonin release assay (7).

Unfortunately there have not been any comparably designed, prospective, large-scale trials investigating the frequency of HIT in patients receiving full-dose intravenous heparin. However, pooled analyses derived from less rigorous prospective studies suggest that HIT becomes more common after full-dose intravenous heparin than after subcutaneous heparin (8,9). The reported frequency of HIT type II in this patient group ranges from 0% to 30%, reflecting the varying

From the Department of Cardiology, Joseph J. Jacobs Center for Vascular Biology and Department of Clinical Pathology, The Cleveland Clinic Foundation, Cleveland, Ohio.

Manuscript received June 4, 1997; revised manuscript received February 9, 1998, accepted February 19, 1998.

Address for correspondence: Dr. Eric J. Topol, The Cleveland Clinic Foundation, 9500 Euclid Avenue, Desk F-25, Cleveland, Ohio 44195. E-mail: topole@cesmtp.ccf.org.

Abbreviations and Acronyms

ELISA	= enzyme-linked immunosorbent assay
HIPA	= heparin-induced platelet aggregation
HIT	= heparin-induced thrombocytopenia
Ig	= immunoglobulin
LMW	= low molecular weight
PF4	= platelet factor 4

patient groups studied, different types of heparin used and varying definitions of thrombocytopenia (10).

Although HIT appears to be more common after administration of larger doses of heparin, it may still occur after exposure to very small quantities of the drug. The condition has been described in patients receiving small amounts of heparin in flush solutions used to maintain the patency of indwelling peripheral catheters (11-14) and in patients with heparin-coated pulmonary artery catheters (15).

A number of investigators (16-20) have observed that patients previously exposed to heparin develop HIT earlier after institution of heparin therapy compared with those with no previous exposure, suggestive of an anamnestic response, although the objective evidence for the existence of immunologic memory in these patients is not strong (see later discussion). The small, prospective studies to date have not demonstrated an association between previous treatment with heparin and an increased likelihood of developing HIT (21), and it is anticipated that ongoing, adequately sized, prospective trials will provide a clearer perspective of the impact of previous exposure to heparin on the frequency of this syndrome.

Most prospective studies comparing porcine mucosal with bovine lung heparin have reported a greater frequency of HIT among patients receiving the latter (8,21,22). Individual batches of heparin may have an increased propensity to cause

Figure 1. Incidence of HIT as determined by clinical suspicion and positive in vitro heparin-dependent platelet aggregation assays performed at the Cleveland Clinic Foundation from 1991 to 1996 (data for 1996 were collected from January through October).

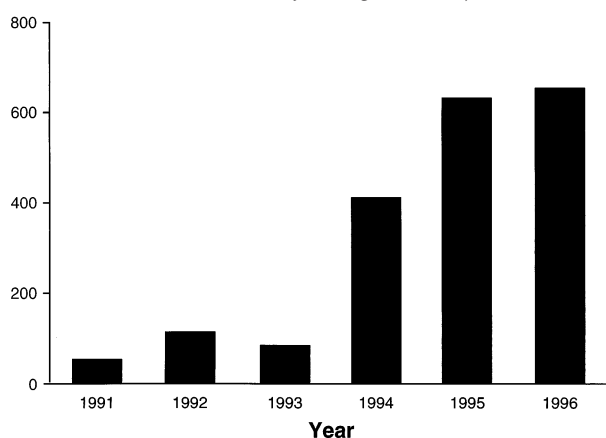


Table 1. Distinguishing Characteristics of the Two Types of Heparin-Induced Thrombocytopenia

	Type I	Type II
Frequency	10-20%	2-30%
Timing of onset	1-4 days	5-10 days
Nadir platelet count	100,000/ μ l	30,000-55,000/ μ l
Antibody mediated	No	Yes
Thromboembolic sequelae	None	30-80%
Hemorrhagic sequelae	None	Rarely
Management	Observe	Cessation of heparin, alternative anticoagulation, additional therapy

thrombocytopenia even when derived from the same source, giving rise to "epidemics" of HIT (23).

Thrombocytopenia and thrombosis are not unique to heparin and have also been described after administration of other sulfated glycosaminoglycans such as LMW heparin, pentosan polysulfate and chondroitin sulfate (24,25). The frequency with which it occurs appears to be directly related to the size and degree of sulfation of the molecule (25).

Frequency of Thromboembolic Events

There is conflicting information in the published data concerning the frequency of thromboembolic events in patients with HIT. Early retrospective studies reported a frequency rate >60%, although this may have reflected the fact that the condition was often not recognized before complications occurred (26-28).

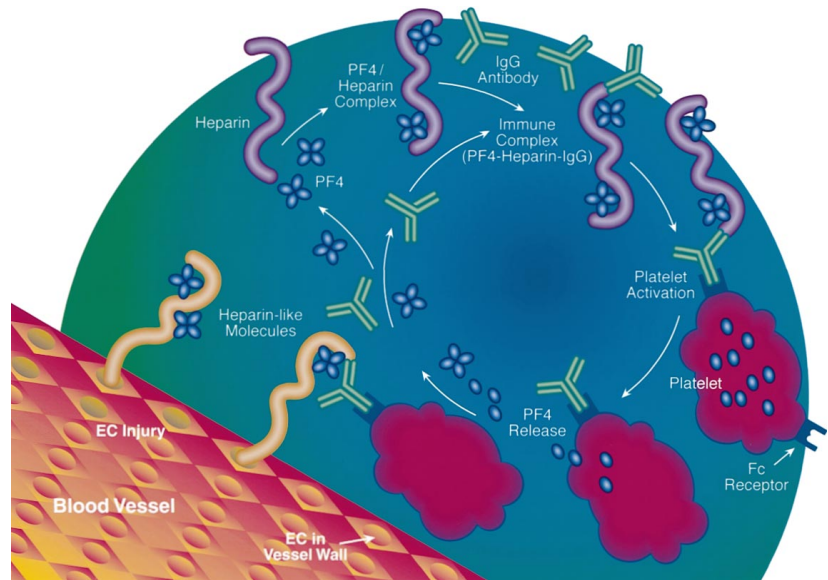
In prospective studies of HIT, only small numbers of patients have developed thrombotic complications (29). When data from the adequately designed studies are pooled, the risk of thrombosis in patients with HIT is estimated at 30% (30). The frequency may vary dramatically with the baseline risk of thrombosis in the patient group. In the study of patients receiving heparin for thromboprophylaxis after hip surgery, 8 (88.9%) of the 9 patients with HIT had one or more thrombotic events as compared with 117 (17.8%) of the 656 patients without HIT (7). Data from a recent, carefully performed, retrospective study suggest that the risk of thrombotic events may persist for several weeks after exposure to heparin (31). In this study of 62 patients diagnosed initially with isolated HIT, >50% experienced thrombotic complications over the ensuing 30 days.

Pathophysiology

Type II HIT is an immune-mediated reaction most commonly caused by an immunoglobulin (Ig) G antibody that binds to platelets in the presence of heparin and causes platelet activation (Fig. 2). Heparin-dependent IgM and IgA antibodies have also been described, and recent evidence suggests that they too may induce type II HIT (32).

The antigen. Despite the important role of heparin in initiating and sustaining the syndrome, it has not been possible

Figure 2. Pathophysiology of HIT syndrome. In susceptible subjects, heparin bound to PF4 results in an antibody response. An IgG antibody directed against a heparin–PF4 complex binds platelets through the Fc receptor. This results in platelet activation and microparticle formation. Platelet-rich thrombi form at sites of preexisting pathology (arterial thrombotic events in patients with atherosclerotic vascular disease) or sites of endothelial injury (e.g., deep venous thrombosis in patients undergoing orthopedic surgery).



to directly demonstrate an interaction between the antibody and heparin alone. In 1992, it was shown that the majority of antibodies generated in HIT recognized a complex between heparin and platelet factor 4 (PF4) (33–35). The antibody is not specific for heparin, but reacts with other sulfated polysaccharides bound to PF4. This cross reactivity increases with size and negative charge of the polysaccharide (36).

In up to 25% of cases the antibody does not recognize the polysaccharide–PF4 complex, indicating that antigens other than PF4 are responsible for some cases of HIT (37). These antigens remain unidentified.

The antibody response. The heparin-dependent IgG generally becomes detectable after 5 to 7 days of heparin therapy. Patients preexposed to heparin may develop HIT sooner after institution of therapy than those receiving heparin for the first time, suggestive of an anamnestic response. However, almost all of these reported events have occurred within days to weeks of the index exposure (16–20,38,39), when the heparin-associated IgG is usually still detectable in the circulation and is presumably responsible for the thrombocytopenia. It is noteworthy that patients with cardiac disease requiring percutaneous or surgical interventions have frequently been exposed to heparin within this time frame. One case of recurrent HIT (40), documented years after the initial episode, reported a time course comparable to the index event, consistent with the mounting of a second primary immune response and absence of immunologic memory.

Platelet activation. In HIT, IgG binds to the antigenic complex (usually heparin–PF4) on the platelet surface, with the activation of platelets through the Fc receptor (FcγRII) (36,41). Platelets from patients with HIT express increased numbers of Fc receptors on their surface. These platelets show an increased tendency to aggregate in the presence of heparin-dependent antibodies (42). Recent evidence suggests that genetic polymorphisms of the Fc receptor, specifically the presence of the FcγRIIA^{His131} allele, may be associated with

a predisposition to HIT (43). Binding of the HIT-IgG to the Fc receptor results in platelet granule release, thromboxane generation, strong platelet aggregation and microparticle release (see late discussion) (44,45).

A recent report suggests that both IgM and IgA can induce HIT complicated by thrombosis (32). As platelets are not known to carry a receptor for IgM or IgA Fc, this suggests that in these instances, platelet activation occurs through Fc-independent mechanisms.

Activation of coagulation. Depletions in the levels of the coagulation factor inhibitors protein C, heparin cofactor II and antithrombin III have been reported in patients during the thrombocytopenic phase of HIT and normalize after resolution of the thrombocytopenia (28). Disseminated intravascular coagulation is also seen, although not commonly (21). The heparin-associated platelet activation and aggregation consequent on production of the antibody are associated with the generation of platelet-derived microparticles with procoagulant activity (46), and this, possibly together with endothelial activation (see later discussion), may contribute to the generalized activation of the coagulation cascade.

Endothelial cell activation. In vitro studies have provided suggestive evidence that endothelial cell activation may contribute to the pathophysiologic sequelae of HIT. Serum samples from patients with HIT have increased amounts of IgG, IgM and IgA on endothelial cells, stimulating the release of tissue factor (47). The binding of both IgG and IgM HIT antibodies to endothelial cells requires the presence of PF4 but not heparin (41). Binding is reduced when the cells are incubated with heparinase, suggesting that this interaction is mediated in part by endogenous heparin-like molecules such as heparan sulfate found on the surface of endothelial cells (48).

However, the in vivo contribution of endothelial cell activation and procoagulant activity to the thrombotic sequelae of HIT has been challenged for several reasons (29). First, the

risk of thrombosis generally decreases quickly after cessation of heparin, despite the fact that the antibody can often be demonstrated for several weeks (49). In addition, thromboemboli tend to be located at sites of vascular injury rather than being diffusely distributed throughout the vascular tree (17,28), suggesting that endothelial disruption rather than integrity may provide the focus for the thrombogenic response.

Clinical Presentation of HIT

Thrombocytopenia. Thrombocytopenia usually commences between 6 and 12 days after instituting therapy (30). The platelet count typically drops to between 30,000 and 55,000/ μ l, a feature that distinguishes HIT from other forms of drug-induced immune thrombocytopenia, which are typically associated with more precipitous falls in the platelet count (30). However, counts as low as 5,000/ μ l have been reported in patients with HIT (26).

Thrombosis. Thromboembolic events are always accompanied by a fall in the platelet count, usually to thrombocytopenic levels (9), and the mean platelet count in patients with HIT who develop thromboses tend to be lower than that in those who do not develop thromboses (31). However, in any individual patient the risk of a thrombotic event cannot be predicted from the platelet count, and complications in the absence of absolute thrombocytopenia have been reported (50–52). The most common thrombotic complications attributed to HIT have been arterial events resulting in lower limb ischemia, cerebrovascular accident or myocardial infarction (19,26,28,49,51,53–55). Arterial thrombotic episodes at many other sites have also been reported, including arterial graft thrombosis (26,52,55,56), upper limb arterial thrombosis (26,57), renal artery thrombosis (18), mesenteric ischemia (49), spinal artery thrombosis (44), aortic thrombosis (53,58), splenic infarction (59), thrombosis of cardiac chambers (60) and adrenal thrombosis resulting in acute adrenal insufficiency (61). These events, when they occur, often have serious sequelae; it has been estimated that patients with HIT and arterial thrombosis have a mortality rate of ~30% and have a risk of leg amputation of ~20% (20).

Extension of venous thrombosis with recurrent pulmonary embolism has frequently been described in patients after onset of HIT (62–64). Venothrombotic events may be severe—for instance, the progression of venous thrombosis to phlegmasia cerulea dolens, in some cases requiring amputation (53,56). Other reported venous thrombotic events include renal vein thrombosis (13), cerebral venous thrombosis (27) and thrombosis of the upper limb veins (53). Thromboses frequently occur at multiple sites (65,66), and arterial and venous events may occur together (28,54).

Predictors of risk and nature of thrombotic event. A number of studies have suggested that thrombotic events are more likely to occur at sites of preexisting pathology. In one reported series of 25 patients developing HIT and arterial or venous thrombosis, 19 had passage of an arterial or venous catheter or an intraaortic balloon counterpulsation device in

the affected extremity (17). Similarly, Singer et al. (55) reported a series of four patients who developed thrombotic complications of HIT requiring limb amputation after cardiopulmonary bypass, all of whom had previous intravascular devices at those sites. A recent detailed review of 53 patients with HIT identified an association between cardiovascular disease (myocardial infarction or cardiovascular surgery) and arterial thrombotic events. These investigators also noted a recent operation to be strongly associated with venous thrombosis (28). In patients receiving heparin after a cerebrovascular accident, 7 of 21 patients with a significant fall in the platelet count experienced an arterial thrombotic event, either extension of their cerebrovascular accident or a myocardial infarction. There were no venous thrombotic events reported in this patient group (51).

Less common manifestations. *Premonitory symptoms.* Skin necrosis occurring at sites of subcutaneous administration, thought to be mediated by microvascular thrombosis (67), may precede the development of thrombocytopenia (68,69). Administration of intravenous heparin to patients with these lesions may be catastrophic, with the development of severe systemic thromboembolic complications (38,67,70). Acute systemic reactions (resembling acute febrile transfusion reactions) to intravenous heparin bolus therapy have been described in patients with preexisting dermal lesions at sites of subcutaneous heparin administration. There have also been several reports of unexplained abdominal or limb pain, thought to be ischemic in origin, heralding thrombosis (54,58).

Heparin resistance. Impending events may also be heralded by the development of increasing heparin requirements to maintain adequate anticoagulation (26,62,71). Although the mechanism underlying this heparin resistance has not been elucidated, it may reflect platelet release of PF4, which has heparin-neutralizing properties (72), or it may be mediated by the production of platelet-derived microparticles with procoagulant activity (46,73).

Hemorrhage. Despite the presence of thrombocytopenia, hemorrhage is less common than thromboembolic complications in these patients, and there is no relation between the degree of thrombocytopenia and the likelihood of bleeding complications (49). However, when they occur, bleeding complications may be severe and have included intracranial (74), retroperitoneal (75), gastrointestinal (59) or adrenal hemorrhage (76,77). Patients undergoing bypass surgery may be more prone to the bleeding manifestations of HIT (59).

Impact of HIT on patients with cardiovascular disease. There have been several prospective studies investigating the frequency of HIT in patients receiving heparin in the coronary care unit or for coronary artery disease. The reported combined frequency of HIT types I and II ranged from 0% to 24%, and none of the patients reported in these studies experienced thrombotic events (21,39,78,79). Several early reports cited patients who developed deep venous thrombosis or pulmonary embolus associated with thrombocytopenia while receiving heparin for thromboprophylaxis after acute myocardial infarction (27,80,81). Heparin therapy has been used more aggres-

sively in recent years, with the recognition of the integral role of intracoronary thrombus formation in the development of the acute coronary syndromes. In a recent analysis of 1,000 patients enrolled in four consecutive prospective thrombolytic trials, thrombocytopenia defined as either platelet counts <100,000/ml or less than half baseline, occurred in 16.4% of patients, and these patients had a higher in-hospital mortality rate and a more complicated hospital course than patients without thrombocytopenia (82). In a significant number of these patients the fall in the platelet count occurred after 5 to 10 days (median 4) of heparin therapy, suggesting that HIT contributed to some of the detected thrombocytopenia.

Patients undergoing bypass surgery for coronary artery disease have usually been exposed to heparin previously and require large doses for thromboprophylaxis during bypass surgery. Retrospective studies have reported a frequency of HIT in these patients of between 0.5% and 1.9% (55,59,83). In one of these reports, late recognition of the condition (i.e., postoperatively) was associated with a high frequency of bleeding (53%), arterial and venous thromboembolic complications (44%) and death (33%) (59).

Heparin is also routinely used during percutaneous coronary interventions, and these patients, too, have usually been exposed to the drug previously. Several patients have been described in whom an acute myocardial infarction occurred during coronary angioplasty in association with the abrupt onset of HIT (84,85). An association between femoral artery or venous punctures for cardiac catheterization, angiography or insertion of intraaortic balloon counterpulsation devices and arterial or venous thrombosis in the instrumented limbs of patients with HIT has been reported (17).

Diagnosis

HIT should be suspected in any patient who develops thrombocytopenia (<150,000/ μ l) or a 50% or greater fall in the platelet count after 5 days of heparin therapy (7). The platelet count should be repeated and the blood film examined to exclude platelet clumping causing pseudothrombocytopenia (86). After confirmation of the low platelet count, the diagnosis of HIT may be made according to the following criteria: 1) occurrence of thrombocytopenia during heparin administration; 2) exclusion of other causes of thrombocytopenia such as infection, drugs and autoimmune thrombocytopenia; 3) resolution of thrombocytopenia after cessation of heparin therapy; and 4) demonstration of a heparin-dependent platelet antibody by an *in vitro* test (6). Criteria 1 and 2 only are required for the diagnosis of HIT type I. As in most hospitals, *in vitro* confirmation requires analysis of samples in a reference laboratory (see later discussion); the initial diagnosis of HIT is often made on clinical grounds (criteria 1, 2 and 3).

In the absence of thrombocytopenia, HIT should also be considered if a patient receiving heparin experiences a new thrombosis or develops heparin resistance or (rarely) skin necrosis at sites of heparin administration.

Laboratory Studies for the Heparin-Dependent Platelet Antibody

A variety of laboratory tests for the detection of heparin-dependent platelet antibodies have been described (33,45, 87,88). The most widely used is the platelet aggregation test, which measures the aggregation of normal donor platelets by patient serum or plasma in the presence of heparin. This test is popular because it is simple, inexpensive and based on a technique that is already in use in most hemostatic laboratories and can provide a result within 2 to 3 h (10). Although it has a specificity of ~90%, the sensitivity is reported to be between 30% and 50% (37,89-91), which, in the view of some investigators, limits its clinical usefulness (30). However, when performed under optimal conditions, with appropriate positive and negative controls, using donor platelets from individuals known to be highly reactive to the antibody, the sensitivity of the test is reported to exceed 80% (88). Using washed platelets (prepared as for the two-point ¹⁴C-serotonin release assay [see later discussion]) in place of platelet-rich plasma for the aggregation assay may increase its sensitivity and specificity (heparin-induced platelet aggregation [HIPA] test) (92).

The currently accepted reference standard for the laboratory diagnosis of HIT is the two point ¹⁴C-serotonin release assay (45). In this assay, radiolabeled, washed platelets from reactive donors are incubated with heat-treated patient serum in the presence of heparin. The test is positive if ¹⁴C-serotonin release occurs at therapeutic (0.1 U/ml) but not high (100 U/ml) heparin concentrations. It is technically demanding, uses radioactivity and is timing consuming, and therefore usually performed in a reference laboratory and used to confirm rather than to make the diagnosis of HIT (93).

A number of investigators have adapted the enzyme-linked immunosorbent assay (ELISA) technique to devise diagnostic tests for HIT (33,87,91). The most recent of these uses immobilized PF4 bound to heparin as a target for the HIT antibody (33). Initial studies reported PF4 ELISA to be at least as sensitive as both the ¹⁴C-serotonin release and HIPA assays, although discrepant results occur in up to 25% of patients, indicating that the different assays recognize different patient cohorts (37,94). Two recent studies evaluating this assay in patients after cardiopulmonary bypass surgery have reported the heparin-associated antibody to be detectable in >50% of patients by the time of hospital discharge (95,96). The presence of antibody was not predictive of either thrombocytopenia or thromboembolic complications (96), suggesting that the increased sensitivity may be of limited clinical utility in this setting. Further evaluation of this assay will be required before its integration into routine clinical practice.

Prevention

The most important principle of prevention is to minimize the exposure to heparin. In patients with established venous thrombosis, early commencement of warfarin shortens the duration of heparin therapy, thus minimizing the likelihood of

developing thrombocytopenia without affecting efficacy (97). Most investigators stress the importance of maintaining a high index of suspicion and performing regular platelet counts in all patients receiving heparin therapy (6,30). This has been predicated on the retrospective observation that prompt diagnosis of the condition with abrupt withdrawal of the drug can substantially reduce the complication and mortality rates (49). However, in a more recent retrospective analysis (31), patients with a diagnosis of HIT had a subsequent 30-day risk of thrombosis >50%, despite cessation of heparin therapy with or without institution of warfarin therapy, suggesting that additional alternative anticoagulant therapy may be necessary in this patient group.

Treatment

HIT type I. Asymptomatic patients developing mild thrombocytopenia in the absence of the heparin-dependent antibody do not require specific treatment. However, it may be difficult to distinguish this condition from early type II; these patients should be closely monitored, and if there is any doubt, heparin should be discontinued.

HIT type II. In patients who develop thrombocytopenia with a positive laboratory test for the heparin-dependent antibody, the cornerstone of therapy is the absolute discontinuation of heparin. It is imperative that all potential sources of heparin be avoided, a task that can be difficult given the ubiquity of the drug in the hospital setting. Platelet transfusions are not recommended, both because bleeding complications are uncommon and thrombotic events can follow the transfusions (62,98). Once heparin is discontinued, the platelet count should begin to increase within 24 to 48 h and reach normal levels by 4 to 5 days (30). For patients with confirmed venous or arterial thrombosis, the selection of substitute anticoagulant therapy is particularly problematic in the United States at present, as there is currently no readily available, effective, alternative antithrombotic drug. If long-term anticoagulation is required, treatment with warfarin should be commenced. However, warfarin may precipitate venous limb gangrene in patients with deep venous thrombosis complicating HIT by producing protein C deficiency without simultaneous inhibition of thrombin generation, so it should not be administered without concomitant use of a rapidly acting anticoagulant agent (99).

Of the alternative anticoagulant therapies that have been tried in patients requiring early management for the thromboembolic manifestations of HIT, LMW heparin, the LMW heparinoid Orgaran and the defibrinogenating agent anicrod have been used most extensively. In the setting of acute coronary disease, however, the most promising therapy is direct thrombin inhibition.

Direct thrombin inhibitors. After anecdotal reports of the successful use of the prototypic direct thrombin inhibitor hirudin in the management of patients with HIT (100,101), a prospective, open-label evaluation of this drug in achieving therapeutic levels of anticoagulation in patients with HIT is

	Heparin	LMW Heparin	LMW Heparinoid
Disaccharide Backbone			 HS (84%) DS (12%) CS (41%)
Mean Molecular Weight	12-15,000	5-8,000	8,000

Figure 3. Structural characteristics of unfractionated heparin, LMW heparin and LMW heparinoids. Unfractionated and LMW heparins are derived from repeating disaccharide subunits of uronate-glucosamine. LMW heparinoid consists of a mixture of heparan sulfate, which is structurally similar to but less heavily sulfated than heparin, chondroitin sulfate and dermatan sulfate. The latter two saccharides are derived from repeating disaccharide subunits of uronate-galactosamine. EC = endothelial cell(s).

under way in Europe. In a recent preliminary report on the first 82 patients enrolled in this study, effective anticoagulation was achieved in the majority. Five patients (6%) had new thromboembolic complications, 7 (8%) had major bleeding events and 3 (4%) had to undergo limb amputation. Six patients died, but all fatal events were due to aggravation of underlying medical problems; none were causally related to hirudin (102).

In the United States, the cost of hirudin, together with a general perception that it performed less well than expected in two recent large-scale trials in patients with acute coronary syndromes (103,104), has discouraged manufacturers from pursuing its further development for management of patients with acute coronary disease. However, these studies did confirm the safety and antithrombotic efficacy of direct thrombin inhibition (105), features which, together with the lack of cross reactivity with the heparin-dependent antibody, render the direct thrombin inhibitors potentially ideal alternatives for HIT.

The synthetic thrombin inhibitor argatroban has been successfully used in patients with HIT (106). One center recently reported a reduction in mortality from 32% in untreated historical control subjects to 18% in argatroban-treated patients with HIT (107). Open-label, prospective studies evaluating argatroban in patients with a history or current evidence of HIT undergoing percutaneous coronary intervention or peripheral vascular procedures are nearing completion in the United States, and it is hoped that the margin of benefit will be sufficient to encourage the further development and marketing of this agent for the management of this condition.

LMW heparins (Fig. 3). Several retrospective reports have shown that LMW heparin administered to patients with HIT in the absence of cross reactivity, as detected by in vitro platelet aggregation assay, results in a favorable outcome, whereas if cross reactivity is demonstrated, there is a significant likelihood of further thrombotic events (54,108). However, when sera

from patients with HIT are tested for reactivity with LMW heparin using the sensitive ¹⁴C-serotonin release or HIPA assays, cross reactivity with unfractionated heparin approaches 100% (37,109). For this reason, LMW heparin therapy should be avoided in patients with HIT (30). However, in the absence of readily available alternatives, if the in vitro platelet aggregation assay does not demonstrate cross reactivity with LMW heparin, it is currently common practice to administer LMW heparin to these patients and monitor them closely for further thrombotic events, persisting thrombocytopenia or the development of a LMW heparin-dependent antiplatelet antibody (10,110) (Fig. 3).

LMW heparinoid. Although it belongs to the same family of drugs as heparin and LMW heparin, the LMW heparinoid Orgaran, which is presently available for compassionate use in the United States, differs from the LMW heparins in a number of ways (Fig. 3C). It is a mixture of sulfated glycosaminoglycans derived from porcine intestinal mucosa and consists of 84% heparan sulfate, 12% dermatan sulfate and 4% chondroitin sulfate (111). In contrast to LMW heparin, each component of Orgaran is structurally distinct from unfractionated heparin (Fig. 3). As a consequence, it has relatively low cross reactivity (10% to 20%) with the heparin-dependent antibody, as determined by aggregation, serotonin release or HIPA assays (37,85,112). In an overview of 230 patients with HIT treated with Orgaran (85), 93% of patients were considered to have responded adequately to the drug during the treatment period. Approximately 26% of the patients died, but in only 7 patients (3%) was the death deemed directly attributable to Orgaran. The use of Orgaran in patients undergoing open heart surgery is potentially limited by the fact that its anticoagulant effect cannot be neutralized by protamine sulfate. Consistent with this, of 19 patients undergoing cardiopulmonary bypass surgery with Orgaran in place of heparin, 11 bled more than expected. Although Orgaran has been demonstrated to be effective in the prevention and treatment of venous thrombosis (113,114), experience in patients with acute coronary disease or in those requiring coronary or vascular surgery outside the contexts cited earlier is limited. Nevertheless, in Canada and Australia, where the drug has been licensed for clinical use for some years, most authorities currently regard Orgaran as the treatment of choice for patients with HIT (10) (T. Warkentin, personal communication, 1997).

Ancrod. This is a rapidly acting defibrinogenating agent derived from the Malayan pit viper; it is immunologically distinct from heparin and does not cause thrombocytopenia. It acts by cleaving fibrinopeptide A from fibrinogen, producing an unstable product that is rapidly removed from the circulation (115). It may be administered intravenously or subcutaneously and is monitored by measuring the fibrinogen concentration. Although ancrod has been used successfully in a number of patients with thrombotic complications of HIT (116-118), it is not readily available in the United States. Furthermore, it does not suppress thrombosis in all cases (T. Warkentin, personal communication, 1997) and should there-

fore be considered a less favorable alternative in these patients.

Antiplatelet agents. In the absence of controlled, prospective data, antiplatelet agents such as aspirin, dipyridamole or dextran have been recommended empirically as adjunctive therapy after cessation of heparin in patients with HIT, both in the presence and absence of thrombosis (6,16,49,119). Antiplatelet agents have also been given with continued administration of heparin in patients in whom cessation of the anticoagulant agent was believed to be undesirable. In a series of 12 patients with HIT requiring urgent open heart surgery with intraoperative heparin, the preoperative administration of aspirin and dipyridamole resulted in no postoperative thromboembolic events and bleeding in only three patients (59). In another small study of 9 patients, however, it was found that although this strategy protected patients from thromboembolic complications, it did not prevent the thrombocytopenia associated with limited heparin reexposure (120). Aspirin is not consistently effective in inhibiting the heparin-dependent antibody in vitro, presumably reflecting the fact that it has an impact on only one of several pathways of platelet activation and aggregation (121,122). Furthermore, even when aspirin does prevent heparin-induced platelet activation in vitro, this does not necessarily predict its efficacy in vivo (50).

Iloprost, a stable prostacyclin analogue with a circulating half-life of 15 to 30 min, consistently blocks heparin-dependent platelet activation and aggregation in vitro (50,123). Intraoperative infusion of Iloprost has permitted the uneventful administration of heparin to patients with a history of HIT undergoing both vascular and cardiac surgery (124-126). At higher doses the drug may cause hypotension requiring coadministration of vasopressor support (125). Although, from the reports cited earlier, this agent showed considerable promise in this setting, it is unfortunately not currently available in the United States. The monoclonal antibody to the platelet glycoprotein IIb/IIIa 7E3 (Reopro) has been shown to prevent heparin-mediated platelet aggregation induced by HIT plasma in vitro (127). Furthermore, recent in vitro studies have demonstrated that Reopro can significantly reduce thrombin generation initiated by tissue factor (128). Although preliminary studies from our laboratory and others (129) suggest Reopro is able to block the heparin-dependent antibody-induced platelet release reactions, platelets from patients with Glanzmann's thrombasthenia lacking the glycoprotein IIb/IIIa receptor can be activated by HIT IgG (34,130,131), suggesting that inhibition of this receptor will not give complete protection against the prothrombotic manifestations of the syndrome.

Other therapies. Surgical intervention such as thrombectomy or embolectomy may be indicated for limb salvage (49,56,124). Insertion of an inferior vena cava filter in patients with proximal deep venous thrombosis or embolism may reduce the risk of further emboli, but has been associated with thrombosis of the inferior vena cava up to the level of the filter (124). There have been isolated case reports of the administration of fibrinolytic agents (streptokinase, urokinase) without

bleeding complications to patients with HIT with deep venous thrombosis (132,133), pulmonary emboli (134) and arterial thrombosis (135).

Small numbers of patients have received plasma exchange therapy in an attempt to remove the heparin-associated IgG. After relatively few treatments (ranging from one to six, generally in association with antiplatelet agents, plasmapheresis has been followed by reversal of the heparin-associated platelet aggregation abnormality, resolution of thrombocytopenia and stabilization of thrombotic phenomena (136–139).

Some preparations of high dose Ig can prevent heparin-associated platelet activation by HIT sera, presumably by competitively inhibiting binding of the HIT-IgG to the platelet Fc receptor (131). Correction of thrombocytopenia after administration of intravenous Ig has been reported in several patients with HIT (30,140).

Readministration of heparin. In patients with heparin-dependent antibodies, as detected by in vitro aggregation studies, reexposure to heparin is associated with a high risk of thrombocytopenia and thrombosis (120). In the majority of patients, the heparin-induced aggregation will disappear within several weeks, although persistence for over 2 years has been documented (49). In some clinical situations, such as cardiopulmonary bypass surgery, where anticoagulation is deemed essential and the safety and efficacy of heparin are well established, some investigators have advocated awaiting disappearance of the heparin-dependent antibody, as monitored by in vitro aggregation studies, and then performing the operation or procedure with full heparinization but without postoperative heparin administration (141). Although anecdotal, this approach has been successful. However, it may prove dangerous in those patients for whom the available in vitro assay is not sufficiently sensitive to detect a pathophysiologically potent antibody (89) or for the occasional patient in whom severe HIT can be provoked by reexposure to heparin.

HIT with thrombosis can recur years after a previous episode, even when a negative platelet aggregation test has been confirmed after the initial event (40). In general, patients with a history of HIT should therefore be advised to avoid further heparin exposure for life.

Conclusions

HIT is encountered more frequently in the practice of cardiology as the application of anticoagulant therapy becomes more generalized. The thrombotic complications of HIT are associated with significant morbidity and mortality and can only be prevented by early recognition of the condition. It is therefore imperative that cardiologists maintain a high index of suspicion and perform frequent platelet counts in all patients receiving heparin therapy. Once HIT is diagnosed, heparin must be stopped immediately and eliminated from all infusion lines and flushes. In most cases, alternative anticoagulant therapy should be initiated—a task made difficult at present by the absence of a readily available alternative anticoagulant agent with proven efficacy in patients with acute coronary

disease. Several direct thrombin inhibitors are being evaluated in patients with HIT, and it is hoped that the margin of benefit will be sufficient to encourage the manufacturers to make this drug available for the management of this potentially life-threatening complication of heparin therapy.

References

1. Ware J, Salzman E. Use of heparin in treatment of thromboembolic disorders. In: Lane D, Lindahl U, editors. Heparin: Chemical and Biological Properties, Clinical Applications. London, Melbourne, Auckland: Edward Arnold, 1989:475–94.
2. The RISC Group. Risk of myocardial infarction and death during treatment with low dose aspirin and intravenous heparin in men with unstable coronary disease. *Lancet* 1990;336:827–30.
3. Theroux P, Quimet H, McCans J, et al. Aspirin, heparin, or both to treat acute unstable angina. *N Engl J Med* 1988;319:1105–11.
4. Granger CB, Hirsh JH, Calif RM, et al. Activated partial thromboplastin time and outcome after thrombolytic therapy for acute myocardial infarction: results from the GUSTO-1 trial. *Circulation* 1996;93:870–8.
5. Hirsh J, Fuster V. Guide to anticoagulant therapy. Part 1: Heparin. *Circulation* 1994;89:1449–68.
6. Chong BH. Heparin-induced thrombocytopenia. *Aust N Z J Med* 1992;22:145–52.
7. Warkentin TE, Levine MN, Hirsh J, et al. Heparin-induced thrombocytopenia in patients treated with low-molecular-weight heparin or unfractionated heparin. *N Engl J Med* 1995;332:1330–5.
8. Schmitt BP, Adelman B. Heparin-associated thrombocytopenia: a critical review and pooled analysis. *Am J Med Sci* 1993;305:208–15.
9. Warkentin TE, Kelton JG. Heparin and platelets. *Hematol Oncol Clin North Am* 1990;4:243–64.
10. Chong BH. Heparin-induced thrombocytopenia. *Br J Haematol* 1995;89:431–9.
11. Doty JR, Alving BM, McDonnell DE, Ondra SL. Heparin-associated thrombocytopenia in the neurosurgical patient. *Neurosurgery* 1986;19:69–72.
12. Brushwood DB. Hospital liable for allergic reaction to heparin used in injection flush. *Am J Hosp Pharm* 1992;49:1491–2.
13. Rizzoni WE, Miller K, Rick M, Lotze MT. Heparin-induced thrombocytopenia and thromboembolism in the postoperative period. *Surgery* 1987;103:470–6.
14. Heeger PS, Backstrom JT. Heparin flushes and thrombocytopenia [letter]. *Ann Intern Med* 1986;105:143.
15. Laster J, Silver D. Heparin-coated catheters and heparin-induced thrombocytopenia. *J Vasc Surg* 1988;7:667–72.
16. Kapsch D, Silver D. Heparin-induced thrombocytopenia with thrombosis and hemorrhage. *Arch Surg* 1981;116:1423–7.
17. Makhoul RG, Greenberg CS, McCann RL. Heparin-associated thrombocytopenia and thrombosis: a serious clinical problem and potential solution. *J Vasc Surg* 1986;4:522–8.
18. Cimo PL, Moake JL, Weinger RS, Ben-Menachem Y, Khalil KG. Heparin-induced thrombocytopenia: association with a platelet aggregating factor and arterial thromboses. *Am J Hematol* 1979;6:125–33.
19. Chang JC. White clot syndrome associated with heparin-induced thrombocytopenia: a review of 23 cases. *Heart Lung* 1987;16:403–7.
20. King DJ, Kelton JG. Heparin-associated thrombocytopenia. *Ann Intern Med* 1984;100:535–40.
21. Bell WR, Royall RM. Heparin-associated thrombocytopenia: a comparison of three heparin preparations. *N Engl J Med* 1980;303:902–7.
22. Powers PJ, Kelton JG, Carter CJ. Studies on the frequency of heparin associated thrombocytopenia. *Thromb Res* 1984;33:439–43.
23. Stead RB, Schafer AI, Rosenberg RD, Handin RI, Josa M, Khuri SF. Heterogeneity of heparin lots associated with thrombocytopenia and thromboembolism. *Am J Med* 1984;77:185–8.
24. Vitoux JF, Roncato M, Hourdebaigt P, Aiach M, Fiessinger J-N. Heparin-induced thrombocytopenia and pentosan polysulfate: treatment with a low molecular weight heparin despite in vitro platelet aggregation. *Thromb Haemost* 1985;55:294–5.
25. Greinacher A, Michels I, Schafer M, Kiefel V, Mueller-Eckhardt C.

- Heparin-associated thrombocytopenia in a patient treated with polysulphated chondroitin sulphate: evidence for immunological crossreactivity between heparin and polysulphated glycosaminoglycan. *Br J Haematol* 1992;81:252-4.
26. Silver D, Kapsch DN, Tsoi EKM. Heparin-induced thrombocytopenia, thrombosis and hemorrhage. *Ann Surg* 1983;198:301-6.
27. Van Der Weyden MB, Hunt H, McGrath K, et al. Delayed-onset heparin-induced thrombocytopenia. *Med J Aust* 1983;2:132-5.
28. Boshkov LK, Warkentin TE, Hayward CPM, Andrew M, Kelton JG. Heparin-induced thrombocytopenia and thrombosis: clinical and laboratory studies. *Br J Haematol* 1993;84:322-8.
29. Warkentin TE, Kelton JG. Heparin-induced thrombocytopenia. *Prog Hemost Thromb* 1991;10:1-34.
30. Warkentin TE, Kelton JG. Interaction of heparin with platelets, including heparin-induced thrombocytopenia. In: Bounameaux H, editor. *Low-molecular-weight heparins in prophylaxis and therapy of thromboembolic diseases*. New York, Basel, Hong Kong: Marcel Dekker, 1994:75-127.
31. Warkentin TE, Kelton JG. A fourteen year study of heparin induced thrombocytopenia. *Am J Med* 1996;101:502-7.
32. Amiral J, Wolf M, Fischer A-M, Boyer-Neumann C, Vissac A-M, Meyer D. Pathogenicity of IgA and/or IgM antibodies to heparin-PF4 complexes in patients with heparin-induced thrombocytopenia. *Br J Haematol* 1996;92:954-9.
33. Amiral J, Bridey F, Dreyfus M, et al. Platelet factor 4 complexed to heparin is the target for antibodies generated in heparin-induced thrombocytopenia. *Thromb Haemost* 1992;68:95-6.
34. Gruel Y, Boizard-Boval B, Wautier JL. Further evidence that alpha-granule components such as platelet factor 4 are involved in platelet-IgG-heparin interactions during heparin-associated thrombocytopenia. *Thromb Haemost* 1993;70:374-5.
35. Horne MK, Alkins BR. Importance of PF4 in heparin-induced thrombocytopenia: confirmation with gray platelets. *Blood* 1995;85:1408-9.
36. Kelton JG, Smith JW, Warkentin TE, Hayward CPM, Denomme GA, Horsewood P. Immunoglobulin G from patients with heparin-induced thrombocytopenia binds to a complex of heparin and platelet factor 4. *Blood* 1994;83:3232-9.
37. Greinacher A, Amiral J, Dummel V, Vissac A, Kiefel V, Mueller-Eckhardt C. Laboratory diagnosis of heparin-associated thrombocytopenia and comparison of platelet aggregation test, heparin-induced platelet activation test, and platelet factor 4/heparin enzyme-linked immunosorbent assay. *Transfusion* 1994;34:381-5.
38. Platell CFE, Tan EGC. Hypersensitivity reactions to heparin: delayed onset thrombocytopenia and necrotizing skin lesions. *Aust N Z J Surg* 1986;56:621-3.
39. Nelson JC, Lerner RG, Goldstein R, Cagin NA. Heparin-induced thrombocytopenia. *Arch Intern Med* 1978;138:548-52.
40. Gruel Y, Lang M, Darnige L, et al. Fatal effect of re-exposure to heparin after previous heparin-associated thrombocytopenia and thrombosis. *Lancet* 1990;336:1077-8.
41. Visentin GP, Ford SE, Scott JP, Aster RH. Antibodies from patients with heparin-induced thrombocytopenia/thrombosis are specific for platelet factor 4 complexed with heparin or bound to endothelial cells. *J Clin Invest* 1994;93:81-8.
42. Chong BH, Pilgrim RL, Cooley MA, Chesterman CN. Increased expression of platelet IgG Fc receptors in immune heparin-induced thrombocytopenia. *Blood* 1993;81:988-93.
43. Burgess AK, Lindeman R, Chesterman CN, Chong BH. Single amino acid mutation of Fc γ receptor is associated with the development of heparin-induced thrombocytopenia. *Br J Haematol* 1995;91:761-6.
44. Chong BH, Pitney WR, Castaldi PA. Heparin-induced thrombocytopenia: association of thrombotic complications with heparin-dependent IgG antibody that induces thromboxane synthesis and platelet aggregation. *Lancet* 1982;2:1246-9.
45. Sheridan D, Carter C, Kelton JG. A diagnostic test for heparin-induced thrombocytopenia. *Blood* 1986;67:27-30.
46. Warkentin TE, Hayward CPM, Boshkov LK, et al. Sera from patients with heparin-induced thrombocytopenia generate platelet derived microparticles with procoagulant activity: an explanation for the thrombotic complications of heparin-induced thrombocytopenia. *Blood* 1994;84:3691-9.
47. Cines DB, Tomaski A, Tannenbaum S. Immune endothelial-cell injury in heparin-associated thrombocytopenia. *N Engl J Med* 1987;316:581-9.
48. Damus PS, Hicks M, Rosenberg RD. A generalized view of heparin's anticoagulant action. *Nature* 1973;246:355-7.
49. Laster J, Cikrit D, Walker N, Silver D. The heparin-induced thrombocytopenia syndrome: an update. *Surgery* 1987;102:763-70.
50. Kappa JR, Fisher CA, Berkowitz HD, Cottrell ED, Addonizio VP. Heparin-induced platelet activation in sixteen surgical patients: diagnosis and management. *J Vasc Surg* 1987;5:101-9.
51. Ramirez-Lassepas M, Cipolle RJ, Rodvold KA, et al. Heparin-induced thrombocytopenia in patients with cerebrovascular ischaemic disease. *Neurology* 1984;34:736-40.
52. Hach-Wunderle V, Kainer K, Krug B, Muller-Berghaus G, Potsch B. Heparin associated thrombosis despite normal platelet counts. *Lancet* 1994;344:469-70.
53. Stanton PE, Evans JR, Lefemine AA, et al. White clot syndrome. *South Med J* 1988;81:616-20.
54. Leroy J, Leclerc MH, Delahousse B, et al. Treatment of heparin-associated thrombocytopenia and thrombosis with low molecular weight heparin (CY 216). *Semin Thromb Hemost* 1985;11:326-9.
55. Singer RL, Mannion JD, Bauer TL, Armenti FR, Edie RN. Complications from heparin-induced thrombocytopenia in patients undergoing cardiopulmonary bypass. *Chest* 1993;104:1036-40.
56. Towne JB, Bernhard VM, Hussey C, Garancis JC. White clot syndrome: peripheral vascular complication of heparin therapy. *Arch Surg* 1979;114:372-7.
57. Thomas D, Block AJ. Thrombocytopenia, cutaneous necrosis, and gangrene of the upper and lower extremities in a 35-year-old man. *Chest* 1992;102:1578-80.
58. Baird RA, Convery FR. Arterial thromboembolism in patients receiving systemic heparin therapy: a complication associated with heparin-induced thrombocytopenia. *J Bone Joint Surg* 1977;59A:1061-4.
59. Walls JT, Curtis JJ, Silver D, Boley TM, Schmaltz RA, Nawarawong N. Heparin-induced thrombocytopenia in open heart surgical patients: sequelae of late recognition. *Ann Thorac Surg* 1992;53:787-91.
60. Guittard M, Pradalier A, Vincent D, Dry J. Thrombose intraventriculaire droite et thrombopenie a l-heparine [letter]. *Presse Med* 1988;17:871.
61. Arthur CK, Grant SJB, Murray WK, Isbister JP, Stiel JN, Lauer CS. Heparin associated acute adrenal insufficiency. *Aust N Z J Med* 1985;15:454-5.
62. Van Damme H, Damas P, David JL, Limet R. Heparin-induced thrombocytopenia: a case report. *Angiology* 1990;41:1075-81.
63. Rhodes GR, Dixon RH, Silver D. Heparin induced thrombocytopenia with thrombotic and hemorrhagic manifestations. *Surg Gynaecol Obstet* 1973;136:409-16.
64. Gallus AS, Goodall KT, Tillett J, Jackaman J, Wycherley A. The relative contribution of antithrombin III during heparin treatment, and of clinically recognisable risk factors, to early recurrence of venous thromboembolism. *Thromb Res* 1987;46:539-53.
65. Sandler RM, Seifer DB, Morgan K, et al. Heparin-induced thrombocytopenia and thrombosis: detection and specificity of a platelet aggregating IgG. *Am J Clin Pathol* 1985;83:760-4.
66. Weismann RE, Tobin RW. Arterial embolism occurring during systemic heparin therapy. *Arch Surg* 1958;76:219-27.
67. White PW, Sadd JR, Nensel RE. Thrombotic complications of heparin therapy, including six cases of heparin-induced skin necrosis. *Ann Surg* 1978;190:595-608.
68. Ulrick PJ, Manoharan A. Heparin-induced skin reaction. *Med J Aust* 1984;140:287-9.
69. Hartman AR, Hood RM, Anagnostopoulos CE. Phenomenon of heparin-induced thrombocytopenia associated with skin necrosis. *J Vasc Surg* 1988;7:781-4.
70. Fowlie J, Stanton PD, Anderson JR. Heparin-associated skin necrosis. *Postgrad Med J* 1990;66:573-5.
71. Ansell J, Deykin D. Heparin-induced thrombocytopenia and recurrent thromboembolism. *Am J Hematol* 1980;8:325-32.
72. Padilla A, Gray E, Pepper DS, Barrowcliffe TW. Inhibition of thrombin generation by heparin and low molecular weight (LMW) heparins in the presence and absence of platelet factor 4 (PF4). *Br J Haematol* 1992;82:406-13.
73. Bode AP, Eick L. Lysed platelets shorten the activated coagulation time (ACT) of heparinized blood. *Am J Clin Pathol* 1989;91:430-4.

74. Kapsch DN, Adelstein EH, Rhodes GR, Silver D. Heparin-induced thrombocytopenia, thrombosis, and hemorrhage. *Surgery* 1979;86:148-55.
75. Lynch DM, Howe SE. Heparin-associated thrombocytopenia: antibody binding specificity to platelet antigens. *Blood* 1985;66:1176-81.
76. Souid F, Pourria JL, Le Roux G, Hoang P. Adrenal haemorrhagic necrosis related to heparin-associated thrombocytopenia. *Crit Care Med* 1991;19:297-9.
77. Bleasel JF, Rasko JEJ, Rickard KA, Richards G. Acute adrenal insufficiency secondary to heparin-induced thrombocytopenia-thrombosis syndrome. *Med J Aust* 1992;157:192-3.
78. Malcolm ID, Wigmore TA. Thrombocytopenia induced by low-dose subcutaneous heparin [letter]. *Lancet* 1978;1:444.
79. Johnson RA, Lazarus KH, Henry DH. Heparin-induced thrombocytopenia: a prospective study. *Am J Hematol* 1984;17:349-53.
80. Gallus AS, Goodall KT, Beswick W, Chesterman CN. Heparin-associated thrombocytopenia: case report and prospective study. *Aust N Z J Med* 1980;10:25-31.
81. Green D, Harris K, Reynolds N, Roberts M, Patterson R. Heparin immune thrombocytopenia: evidence for a heparin-platelet complex as the antigenic determinant. *J Lab Clin Med* 1978;91:167-75.
82. Harrington RA, Sane DC, Calif RM, et al. Clinical importance of thrombocytopenia occurring in the hospital phase after administration of thrombolytic therapy for acute myocardial infarction. *J Am Coll Cardiol* 1994;23:891-8.
83. Hanson EC, Levine FH. Hyperlipoproteinemia as a significant risk factor for pulmonary embolism in patients undergoing coronary bypass grafting. *Ann Thorac Surg* 1982;33:593-8.
84. Gupta BK, Savage MP, Brest AN. Acute myocardial infarction during coronary angioplasty associated with heparin-induced thrombocytopenia. *Cathet Cardiovasc Diagn* 1995;35:42-6.
85. Magnani HN. Heparin-induced thrombocytopenia (HIT): an overview of 230 patients treated with Orgaran (Org 10172). *Thromb Haemost* 1993;70:554-61.
86. Lecrubier C, Conrad J, Horellou M, Khar H, Samama M. Spontaneous platelet aggregation in heparin-treated patients. *Acta Haematol* 1984;71:63-5.
87. Gruel Y, Rupin A, Darnige L, et al. Specific quantification of heparin-dependent antibodies for the diagnosis of heparin-associated thrombocytopenia using an enzyme-linked immunosorbent assay. *Thromb Res* 1991;62:377-87.
88. Chong BH, Burgess J, Ismail F. The clinical usefulness of the platelet aggregation test for the diagnosis of heparin-induced thrombocytopenia. *Thromb Haemost* 1993;69:344-50.
89. Kelton JG, Sheridan D, Brain H, Powers PJ, Turpie AG, Carter CJ. Clinical usefulness of testing for a heparin-dependent platelet-aggregating factor in patients with suspected heparin-associated thrombocytopenia. *J Lab Clin Med* 1984;103:606-12.
90. Favalaro EJ, Bernal-Hoyos E, Exner T, Koutts J. Heparin-induced thrombocytopenia: laboratory investigation and confirmation of diagnosis. *Pathology* 1992;24:177-83.
91. Howe SE, Lynch DM. An enzyme-linked immunosorbent assay for the evaluation of thrombocytopenia induced by heparin. *J Lab Clin Med* 1985;105:554-9.
92. Greinacher A, Michels I, Kiefel V, Mueller-Eckhardt C. A rapid and sensitive test for diagnosing heparin-associated thrombocytopenia. *Thromb Haemost* 1991;66:734-6.
93. Kelton JG, Warkentin TE. Diagnosis of heparin-induced thrombocytopenia: still a journey, not yet a destination. *Am J Clin Pathol* 1995;104:611-3.
94. Arepally G, Reynolds C, Tomaski A, et al. Comparison of PF4/heparin ELISA assay with the ¹⁴C-serotonin release assay in the diagnosis of heparin-induced thrombocytopenia. *Am J Clin Pathol* 1995;104:648-54.
95. Visentin GP, Malik M, Cyganiak KA, Aster RH. Patients treated with unfractionated heparin during open heart surgery are at high risk to form antibodies reactive with heparin:platelet factor 4 complexes. *J Lab Clin Med* 1996;128:376-83.
96. Bauer TL, Arepally G, Konkle BA, et al. Prevalence of heparin-associated antibodies without thrombosis in patients undergoing cardiopulmonary bypass surgery. *Circulation* 1997;95:1242-6.
97. Gallus A, Jackaman J, Tillett J, Mills W, Wycherley A. Safety and efficacy of warfarin started early after submassive venous thrombosis or pulmonary embolism. *Lancet* 1986;2:1293-6.
98. Babcock RB, Dumper CW, Scharfman WB. Heparin-induced immune thrombocytopenia. *N Engl J Med* 1976;295:237-41.
99. Warkentin TE, Russett JI, Johnston M, Kelton JG. Warfarin treatment of deep vein thrombosis complicating heparin-induced thrombocytopenia (HIT) is a risk factor for initiation of venous limb gangrene: report of nine patients implicating the interacting procoagulant effects of the two anticoagulant agents [abstract]. *Thromb Haemost* 1995;73:1110.
100. Schiele F, Vuilleminot A, Kramarz P, et al. Use of recombinant hirudin as antithrombotic treatment in patients with heparin-induced thrombocytopenia. *Am J Hematol* 1995;50:20-5.
101. Nand S. Hirudin therapy for heparin-associated thrombocytopenia and deep venous thrombosis. *Am J Hematol* 1993;43:310-11.
102. Ferguson TJ. Meeting highlights: the 1995 European Society of Cardiology. *Circulation* 1995;92:2359-63.
103. The Global Use of Strategies to Open Occluded Coronary Arteries (GUSTO) IIb Investigators. A comparison of recombinant hirudin with heparin for the treatment of acute coronary syndromes. *N Engl J Med* 1996;335:775-82.
104. Antman EM, for the TIMI 9B Investigators. Hirudin in acute myocardial infarction: Thrombolysis and thrombin inhibition in Myocardial Infarction (TIMI 9B) trial. *Circulation* 1996;94:911-21.
105. Brieger DB, Topol EJ. Hirudin in acute coronary syndromes: when cents override good sense. *Thromb Thrombolysis* 1997;4:327-9.
106. Matsuo T, Kazuomi K, Chikahira Y, Nakao K, Yamada T. Treatment of heparin-induced thrombocytopenia by use of argatroban, a synthetic thrombin inhibitor. *Br J Haematol* 1992;82:627-9.
107. Lewis BE, Walenga JM, Wallis DE. Anticoagulation with Novastan (argatroban) in patients with heparin-induced thrombocytopenia and heparin-induced thrombocytopenia and thrombosis syndrome. *Semin Thromb Haemost* 1997;23:197-202.
108. Gouault-Heilmann M, Huet Y, Adnot S, et al. Low molecular weight heparin fractions as an alternative therapy in heparin-induced thrombocytopenia. *Haemostasis* 1987;17:134-40.
109. Greinacher A, Michels I, Mueller-Eckhardt C. Heparin-associated thrombocytopenia: the antibody is not heparin specific. *Thromb Haemost* 1992;67:545-9.
110. Ramakrishna R, Manoharan A, Kwan YL, Kyle PW. Heparin-induced thrombocytopenia: cross-reactivity between standard heparin, low molecular weight heparin, dalteparin (Fragmin) and heparinoid, danaparoid (Orgaran). *Br J Haematol* 1995;91:736-8.
111. Meuleman DG. Orgaran (Org 10172): its pharmacologic profile in experimental models. *Haemostasis* 1992;22:58-65.
112. Chong BH, Ismail F, Cade J, Gallus A, Gordon S, Chesterman CN. Heparin-induced thrombocytopenia: studies with a new low molecular weight heparinoid, Org 10172. *Blood* 1989;73:1592-6.
113. Bachmann F, Leyvraz P. Low molecular weight heparins for the prevention of venous thromboembolism following orthopedic surgery. In: Bounameaux H, editor. *Low Molecular Weight Heparins in Prophylaxis and Therapy of Thromboembolic Diseases*. New York: Marcel Dekker, 1994:187-212.
114. de Valk HW, Banga JD, Wester JWJ, et al. Comparing subcutaneous danaparoid with intravenous unfractionated heparin for the treatment of venous thromboembolism: a randomized controlled trial. *Ann Intern Med* 1995;123:1-9.
115. Bell WR, Pitney WR, Goodwin JF. Therapeutic defibrination in the treatment of thrombotic disease. *Lancet* 1968;1:490-3.
116. Teasdale SJ, Zulys VJ, Mycyk T, Baird RJ, Glynn MFX. Ancrod anticoagulation for cardiopulmonary bypass in heparin-induced thrombocytopenia and thrombosis. *Ann Thorac Surg* 1989;48:712-3.
117. Demers C, Ginsberg JS, Brill-Edwards P, et al. Rapid anticoagulation using ancrod for heparin induced thrombocytopenia. *Blood* 1991;78:2194-7.
118. Cole CW, Fournier LM, Bormanis J. Heparin-associated thrombocytopenia and thrombosis: optimal therapy with ancrod. *Can J Surg* 1990;33:207-10.
119. AbuRahma AF, Boland JP, Witsberger T. Diagnostic and therapeutic strategies of white clot syndrome. *Am J Surg* 1991;162:175-9.
120. Laster J, Elfrink R, Silver D. Reexposure to heparin of patients with heparin-associated antibodies. *J Vasc Surg* 1989;9:677-82.
121. Chong BH, Castaldi PA. Heparin-induced thrombocytopenia: further studies of the effects of heparin-dependent antibodies on platelets. *Br J Haematol* 1986;64:347-54.
122. Kappa JR, Fisher CA, Addonizio P. Heparin-induced platelet activation:

- the role of thromboxane A₂ synthesis and the extent of platelet granule release in two patients. *J Vasc Surg* 1989;9:574-9.
123. Schillinger E, Krais T, Lehman M, Stock G. Iloprost. In: Scriabine A, editor. *New Cardiovascular Drugs*. New York: Raven Press, 1986:209-31.
 124. Sobel M, Adelman B, Szentpetery S, Hoffman M, Posner MP, Jenvey W. Surgical management of heparin-associated thrombocytopenia: strategies in the treatment of venous and arterial thromboembolism. *J Vasc Surg* 1988;8:395-401.
 125. Kappa JR, Fisher CA, Todd B, et al. Intraoperative management of patients with heparin-induced thrombocytopenia. *Ann Thorac Surg* 1990;49:714-23.
 126. Gruel Y, Lermusiaux P, Lang M, et al. Usefulness of antiplatelet drugs in the management of heparin-associated thrombocytopenia and thrombosis. *Ann Vasc Surg* 1991;5:552-5.
 127. Mak K-H, Kottke-Marchand K, Brooks LM, Aphaert KL, Topol EJ. Potential value of platelet GPIIb/IIIa antagonist for treating heparin-induced thrombocytopenia (HIT) [abstract]. *J Am Coll Cardiol* 1996;27 Suppl A: 316A.
 128. Reverter JC, Beguin S, Kessels H, Kumar R, Hemker HC, Coller BS. Inhibition of platelet-mediated, tissue factor-induced thrombin generation by the mouse/human chimeric 7E3 antibody. *J Clin Invest* 1996;98:863-74.
 129. Fareed J, Yang L, Hoppensteadt D, Koza M, Walenga JM, Welzel D. Glycoprotein IIb/IIIa inhibitors can prevent heparin mediated platelet activation in heparin-induced thrombocytopenia [abstract]. *Circulation* 1996;94 Suppl I:I-228.
 130. Kelton JG, Sheridan D, Santos A, et al. Heparin-induced thrombocytopenia: laboratory studies. *Blood* 1988;72:925-30.
 131. Greinacher A, Liebenhoff U, Kiefel V, Presek P, Mueller-Eckhardt C. Heparin-associated thrombocytopenia: the effects of various intravenous IgG preparations on antibody mediated platelet activation—a possible new indication for high dose i.v. IgG. *Thromb Haemost* 1994;71:641-5.
 132. Clifton GD, Smith MD. Thrombolytic therapy in heparin-associated thrombocytopenia with thrombosis. *Clin Pharm* 1986;5:597-601.
 133. Mehta DP, Yoder EL, Appel J, Bergsman KL. Heparin-induced thrombocytopenia and thrombosis: reversal with streptokinase. A case report and review of the literature. *Am J Hematol* 1991;36:275-9.
 134. Cohen JI, Cooper MR, Greenberg CS. Streptokinase therapy of pulmonary emboli with heparin-associated thrombocytopenia. *Arch Intern Med* 1985;145:1725-6.
 135. Feissinger JN, Aiach M, Roncato M, Debure C, Gaux JC. Critical ischemia during heparin-induced thrombocytopenia: treatment by intra-arterial streptokinase. *Thromb Res* 1984;33:235-8.
 136. Bouvier JL, Lefevre P, Villain P, et al. Treatment of serious heparin-induced thrombocytopenia by plasma exchange: report on 4 cases. *Thromb Res* 1988;51:335-6.
 137. Nand S, Robinson JA. Plasmapheresis in the management of heparin-associated thrombocytopenia with thrombosis. *Am J Hematol* 1988;28:204-6.
 138. Brady J, Riccio JA, Yumen OH, Makary AZ, Greenwood SM. Plasmapheresis: a therapeutic option in the management of heparin-associated thrombocytopenia with thrombosis. *Am J Clin Pathol* 1991;96:394-7.
 139. Vender JS, Matthew EB, Silverman IM, Konowitz H, Dau PC. Heparin-associated thrombocytopenia: alternative managements. *Anesth Analg* 1986;65:520-2.
 140. Frame JN, Mulvey KP, Phares JC, Anderson MJ. Correction of severe heparin-associated thrombocytopenia with intravenous immunoglobulin. *Ann Intern Med* 1989;111:946-7.
 141. Olinger GN, Hussey CV, Olive JA, Malik MI. Cardiopulmonary bypass for patients with previously documented heparin-induced platelet aggregation. *J Thorac Cardiovasc Surg* 1984;87:673-7.

Heparin-induced thrombocytopenia
DB Brieger, KH Mak, K Kottke-Marchant, and EJ Topol
J. Am. Coll. Cardiol. 1998;31;1449-1459

This information is current as of February 10, 2012

Citations	This article has been cited by 29 HighWire-hosted articles: http://content.onlinejacc.org#otherarticles
Rights & Permissions	Information about reproducing this article in parts (figures, tables) or in its entirety can be found online at: http://content.onlinejacc.org/misc/permissions.dtl
Reprints	Information about ordering reprints can be found online: http://content.onlinejacc.org/misc/reprints.dtl