


**GET HELP FROM
CMS HERE**



Mobile aortic atheroma and systemic emboli: efficacy of anticoagulation and influence of plaque morphology on recurrent stroke

FA Dressler, WR Craig, R Castello, and AJ Labovitz
J. Am. Coll. Cardiol. 1998;31;134-138

This information is current as of February 10, 2012

The online version of this article, along with updated information and services, is located on the World Wide Web at:

<http://content.onlinejacc.org>

JACC

JOURNAL of the AMERICAN COLLEGE of CARDIOLOGY



Mobile Aortic Atheroma and Systemic Emboli: Efficacy of Anticoagulation and Influence of Plaque Morphology on Recurrent Stroke

FREDERICK A. DRESSLER, MD, WILLIAM R. CRAIG, MD, RAMON CASTELLO, MD, FACC,
ARTHUR J. LABOVITZ, MD, FACC

Saint Louis, Missouri

Objectives. We sought to determine the influence of plaque morphology and warfarin anticoagulation on the risk of recurrent emboli in patients with mobile aortic atheroma.

Background. An epidemiologic link between aortic atheroma and systemic emboli has been described both in pathologic and transesophageal studies. Likewise, a few studies have found an increased incidence of recurrent emboli in these patients. The therapeutic implications of these findings has not been studied.

Methods. Thirty-one patients presenting with a systemic embolic event and found to have mobile aortic atheroma were studied. The height, width and area of both immobile and mobile portions of atheroma were quantitated. The dimensions of the mobile component was used to define three groups: small, intermediate and large mobile atheroma. The patients were followed up by means of telephone interview and clinical records, with emphasis on anticoagulant use and recurrent embolic or vascular events.

Results. Patients not receiving warfarin had a higher incidence of vascular events (45% vs. 5%, $p = 0.006$). Stroke occurred in 27% of these patients and in none of those treated with warfarin. The

annual incidence of stroke in patients not taking warfarin was 0.32. Myocardial infarction occurred in 18% of patients also in this group. Taken together, the risk of myocardial infarction or stroke was significantly increased in this group ($p = 0.001$). Forty-seven percent of patients with small, mobile atheroma did not receive warfarin. Recurrent stroke occurred in 38% of these patients, representing an annual incidence of 0.61. There were no strokes in patients with small, mobile atheroma treated with warfarin ($p = 0.04$). Likewise, none of the patients with intermediate or large mobile atheroma had a stroke during follow-up. Only three of these patients had not been taking warfarin.

Conclusions. Patients presenting with systemic emboli and found to have mobile aortic atheroma on transesophageal echocardiography have a high incidence of recurrent vascular events. Warfarin is efficacious in preventing stroke in this population. The dimension of the mobile component of atheroma should not be used to determine the need for anticoagulation.

(J Am Coll Cardiol 1998;31:134-8)

©1998 by the American College of Cardiology

Nearly 40 years have passed since the aorta was first recognized as a source for systemic emboli (1). For most of this period, clinically available studies such as computed tomography and angiography could not assess the integrity of aortic endothelium well. Consequently, clinical studies of aortic atheroma were unfeasible until transesophageal echocardiography (TEE) was introduced in 1977. Using high fidelity TEE imaging, several investigators have reappraised the link between aortic atheroma and systemic emboli (2-19). As in pathologic reports (1,20-22), an increased frequency of prominent aortic atheroma was almost universally described. Protruding atheroma and those containing mobile components

have been associated with high embolic potential. These data not only implicate atheroma in the genesis of emboli but also infer the need for therapy once they are identified. Although thrombus has been suspected as the major constituent of embolic material originating from atheroma, no studies reporting on the efficacy of antithrombotic therapy in preventing recurrent emboli have appeared. Thus, the therapeutic implications of high risk atheroma remain unknown. Several cases of fatal systemic embolization apparently induced by anticoagulant therapy have been reported (23-26). These reports, combined with the hemorrhagic risks of warfarin, have resulted in a therapeutic quandary for the clinician.

The purpose of the present study was to describe the influence of morphologic plaque features and antithrombotic therapy on the risk of recurrent emboli in patients with mobile aortic atheroma.

From the Department of Internal Medicine and Pathology, Saint Louis University Health Sciences Center, Saint Louis, Missouri. This study was funded entirely through the Division of Cardiology, Saint Louis Health Sciences Center.

Manuscript received February 7, 1997; revised manuscript received September 16, 1997, accepted September 29, 1997.

Address for correspondence: Dr. Frederick A. Dressler, Department of Internal Medicine and Pathology, Saint Louis University Health Sciences Center, 3635 Vista-at-Grand Avenue, Saint Louis, Missouri 63110. E-mail: mciversm@wpogate.slu.edu.

To discuss this article on-line, visit the ACC Home Page at www.acc.org/members and click on the JACC Forum

Table 1. Baseline Clinical Characteristics

Age (yr)	66 ± 10
Men	18 (58%)
Women	13 (42%)
Presenting symptom	
Stroke	18 (58%)
TIA	7 (23%)
Peripheral emboli	6 (19%)
Atherosclerosis	
Risk factors	
HTN	26 (74%)
Tobacco smoking	14 (45%)
Diabetes mellitus	10 (32%)
Cholesterolemia	4 (13%)
Family history	5 (16%)
Extraaortic site	20 (65%)
CAD	12 (39%)
Carotid artery narrowing	8 (26%)
PVD	6 (19%)
AAA	3 (10%)

Data presented are mean value ± SD or number (%) of patients. AAA = aneurysm of abdominal aorta; CAD = coronary artery disease; HTN = hypertension; PVD = peripheral vascular disease; TIA = transient ischemic attack.

Methods

Study group. The study group was derived from the 1,390 patients who presented with systemic emboli and underwent TEE at our institution since 1987. The criterion for inclusion was the presence of plaque in the thoracic aorta that contained a mobile component. Mobility was defined as movement independent of the motion of the aortic wall. In-hospital records were reviewed for atherosclerotic risk factors, diseases, cerebral ischemic symptoms and subsequent evaluation. All diagnostic test results were reviewed. Patients presenting with cerebral ischemia and found to have significant ipsilateral carotid artery narrowing ($\geq 60\%$ diameter) were excluded. The suspected side of cerebral ischemia was determined by history or brain scanning, or both. Patients presenting with sudden left hemiparesis, hemiplegia or hemihypesthesia were considered to have had a right cerebral infarction. Patients with aphasia were also suspected of having a left-sided lesion if they were right-handed. Neurovascular ultrasound of the extracerebral and intracerebral arteries was performed in each patient. Those with significant narrowing of a suspect cerebral artery were excluded. Patients in whom symptoms and brain scanning failed to identify a likely cerebral arterial distribution were excluded if one of the cerebral arteries was significantly narrowed. Those with plaques distal to the origin of the left subclavian artery were excluded unless peripheral embolus was the presenting symptom.

Of the 1,390 patients undergoing TEE for systemic emboli, 108 (7.8%) had high risk aortic plaque (protruding ≥ 5 mm or mobile, or both). Of these 108 patients, 31 had mobile plaque and fulfilled entry criteria and they form the study group. There were 18 men (56%) and 13 women (44%) (Table 1). The

patients' mean age was 66 ± 10 years and was similar in men (66 ± 11 years) and women (66 ± 10 years). Stroke was the most common presenting symptom. One or more risk factors for atherosclerosis were present in 28 (90%) and two or more in 19 (61%) of the group (mean 1.8 ± 1.0 per patient). Hypertension (74%) and tobacco smoking (45%) were most frequent. One or more clinically apparent atherosclerotic disease processes (narrowing of one or more systemic arteries) were present in 20 patients (60%): a single site in 10 (32%) and two or more sites in 10 (32%) (mean 1.0 ± 0.8 per patient). Coronary artery narrowing was most frequent (39%), followed by contralateral carotid artery disease (26%), peripheral vascular disease (19%) and aneurysm of the abdominal aorta (10%). One or more atherosclerotic risk factors or symptomatic atherosclerotic disease, or both, were identified in 30 (96%) of 31 patients.

Of the 31 study patients, 25 (81%) presented with cerebrovascular emboli and 6 (19%) with peripheral emboli. Of the 25 patients presenting with cerebrovascular emboli, a suspected arterial distribution was determined by symptoms or computed tomography or magnetic resonance imaging, or a combination of these, in 22. In three patients, the symptoms were vague and cerebral scanning failed to detect an acute infarct. As defined by the exclusion criteria, none of the study patients had significant lumen narrowing ($>60\%$) in a suspect cerebral artery on neurovascular ultrasonography ($n = 27$) or angiography ($n = 4$).

Transesophageal echocardiography. All TEE was performed with a 5-MHz probe. Multiplane probes were used in the majority of studies (53%). Complete examinations of the heart and thoracic aorta were obtained. Each study included a short- or long-axis view, or both, of the ascending, transverse and descending portions of the thoracic aorta. The largest plaque located in a region of the aorta that could have caused the patient's embolic symptoms was selected for quantitative measurement. Short-axis measurement of plaque was obtained only when the imaging plane was thought to be perpendicular to the long axis of the aorta. Likewise, long-axis views were obtained only when the imaging plane appeared to bisect the aortic cylinder. Once the best short- and long-axis images were selected, each plaque was divided into immobile and mobile portions (Fig. 1). The height, width and area of these components were measured in both short- and long-axis views using proprietary computer software. Height was defined as the greatest dimension in a plane perpendicular to the adjacent aortic wall. Width was defined as the greatest dimension in a plane parallel to the adjacent aortic wall. Plaque mobility was quantitated by measurement of greatest excursion (in degrees) during one cardiac cycle. The patients were further subclassified into groups according to the mobile component size: 1) small = diameter ≤ 1 mm; intermediate = diameter >1 mm and area <10 mm²; and 3) large = diameter >1 mm and area ≥ 10 mm².

Anticoagulant therapy and follow-up. The choice of anticoagulant therapy was determined by the referring physician. Of the 31 study patients, 20 (65%) received long-term warfarin

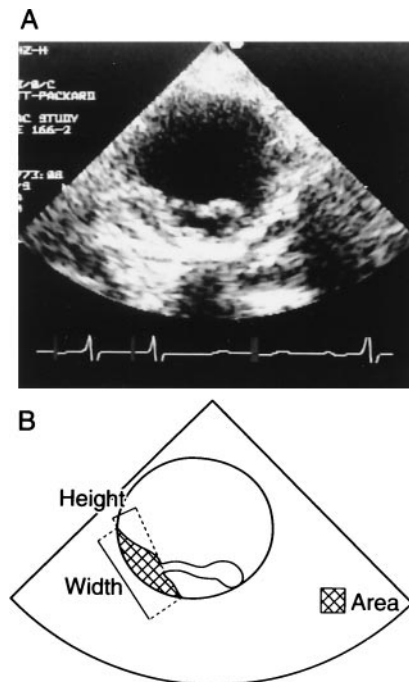


Figure 1. TEE short-axis image (A) and schematic (B) demonstrating quantitation of immobile components of atheroma (cross-hatched area).

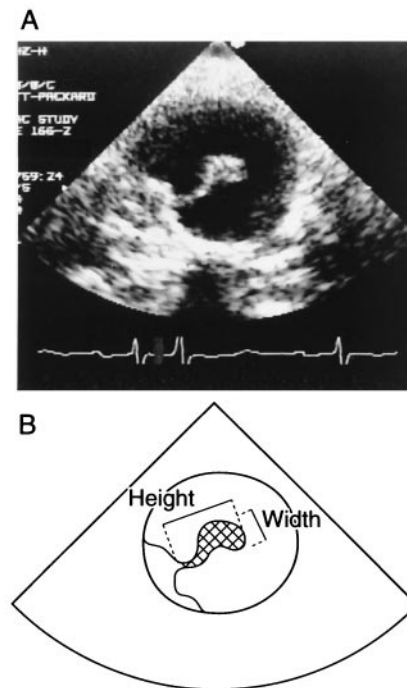


Figure 2. TEE short-axis image (A) and schematic (B) demonstrating quantitation of mobile components of atheroma (cross-hatched area).

therapy. Warfarin was initiated within 1 week of hospital admission and was adjusted to maintain an international normalized ratio of 2.0. The 11 patients (35%) not receiving warfarin were treated with aspirin ($n = 7$) or received no anticoagulant agent ($n = 4$). Follow-up included telephone interview and review of subsequent hospital admissions. The duration of warfarin and antiplatelet therapy (either ticlid or aspirin) was noted. End points included vascular events (stroke, transient ischemic attack, myocardial infarction) and death. All strokes during the follow-up period were confirmed by computed tomography and or magnetic resonance imaging.

Statistics. The clinical and morphologic features of patients treated with and without warfarin were compared using unpaired t tests and contingency table analysis. The influence of plaque morphologic appearance on recurrent emboli was compared using contingency table analysis.

Results

Plaque dimensions. The mean height, width and area of the immobile component of atheroma were 6.6 ± 3.1 mm, 25.8 ± 11.6 mm and 108 ± 57 mm², respectively, and of the mobile component, 8.1 ± 9.6 mm, 3.0 ± 3.1 mm and 42 ± 76 mm², respectively. The mean excursion of the mobile component during the cardiac cycle was $83 \pm 57^\circ$. When the groups with and without warfarin were compared, no significant differences in the immobile component of atheroma were found: height 6.9 ± 3.4 vs. 6.2 ± 2.5 mm; width 24.7 ± 12.0 vs.

27.6 ± 11.1 mm; and area 108 ± 76 vs. 108 ± 57 mm². Although not reaching statistical significance, trends toward a larger mobile component were seen in the group treated with warfarin: height 9.5 ± 11.0 vs. 5.5 ± 4.1 mm ($p = 0.27$); width 3.6 ± 3.5 vs. 1.8 ± 1.4 mm ($p = 0.12$); and area 56 ± 91 vs. 16 ± 10 mm² ($p = 0.16$). The mobility of atheroma was similar between the groups with and without warfarin ($83 \pm 58^\circ$ vs. $85 \pm 57^\circ$, $p = \text{NS}$).

Morphologic groups. The 31 patients with mobile plaques were classified according to morphologic plaque characteristics, as delineated in the Methods section. There were 17 patients (55%) with small, 10 (32%) with intermediate and 4 (13%) with large, mobile atheroma. Although height did not reach statistical significance, the width and area of the immobile component were paradoxically less than those in the large, mobile group compared with the intermediate or small, mobile groups. By definition, each group differed significantly with regard to the mobile component dimension. The degree of excursion (mobility) of the three morphologic groups was similar ($95 \pm 67^\circ$ vs. $69 \pm 47^\circ$ vs. $71 \pm 29^\circ$, respectively, $p = \text{NS}$).

Potential cardiac sources of emboli. In 16 patients (52%), TEE identified one or more potential cardiac embolic sources in addition to aortic atheroma. The treatment groups (with vs. without warfarin) were similar with regard to the frequency of these findings: patent foramen ovale and/or atrial septal aneurysm (27% vs. 25%); atrial fibrillation (0% vs. 5%); dense left atrial spontaneous contrast (0% vs. 5%); and left atrial ap-

Table 2. Plaque Dimensions

Immobile component	
Height (mm)	6.6 ± 3.1
Width (mm)	25.8 ± 11.6
Area (mm ²)	108 ± 63
Mobile component	
Height (mm)	8.1 ± 9.6
Width (mm)	3.0 ± 3.1
Area (mm ²)	42 ± 76
Mobility (degrees)	83 ± 57

Data presented are mean value ± SD.

pendage thrombus (0% vs. 5%). Patients receiving warfarin tended to have a higher frequency of akinetic or severely hypokinetic left ventricular segments (9% vs. 35%, $p = 0.11$).

Events during follow-up. The mean interval from TEE to follow-up was similar between patients treated with warfarin and those going without it (9.5 ± 8.7 vs. 10.8 ± 9.7 months, $p = \text{NS}$). Of the 11 patients not treated with warfarin, 3 (27%) had strokes (Table 2). None of those receiving warfarin had a stroke ($p = 0.07$). The annual incidence of stroke in patients not receiving warfarin was 0.32. Myocardial infarction occurred in two patients, neither of whom had received warfarin. Taken together, the risk for either stroke or myocardial infarction (45%) was significantly increased in this group ($p = 0.006$). There were four deaths: one from stroke in the group not receiving warfarin and three among patients receiving warfarin (sudden cardiac death, gastrointestinal bleed and cancer) ($p = \text{NS}$).

Morphologic groups and recurrent stroke. The influence of anticoagulation on recurrent stroke in the three morphologic groups is presented in Table 3. Of the 17 patients in whom small, mobile plaques were identified, 8 (47%) did not receive warfarin. Recurrent stroke occurred in 3 (38%) of these patients, representing an annual incidence of 0.61. Each of these patients had received long-term aspirin therapy and were taking aspirin (325 mg/day) at the time of the stroke. No strokes occurred in patients with small, mobile atheroma treated with warfarin ($p = 0.04$). Likewise, none of the 14 patients with intermediate ($n = 10$) or large ($n = 4$), mobile atheroma had a stroke during follow-up. Only 3 (21%) of these patients had not been treated with warfarin.

Table 3. Aortic Atheroma: Follow-Up Events

Event	Warfarin (n = 20)	No Warfarin (n = 11)	p Value
Vascular	1 (5%)	5 (45%)	0.006
Stroke	0	3 (27%)	0.07
MI	0	2 (18%)	NS
SD	1 (5%)	0	NS
Death	3 (15%)	1 (9%)	NS
Vascular event or death	4 (20%)	5 (45%)	0.14

Data presented are number (%) of patients. MI = myocardial infarction; SD = sudden death.

Discussion

Although several investigators have described the epidemiologic association between atheroma and systemic emboli both as an index (2–19) and recurrent event (27,28), few studies are available on the appropriate anticoagulant choice in these patients. In the present study, we found that patients with mobile atheroma not treated with warfarin were at high risk (27%) of recurrent stroke. Furthermore, it appears that the morphologic findings on TEE may have influenced the anticoagulant choice. Of patients with intermediate or large, mobile atheroma, only 21% were not placed on warfarin therapy. In contrast, nearly half (47%) of those with small, mobile plaques were not given warfarin. It is likely that the small size of the atheroma persuaded some clinicians to avoid warfarin. The inadequacy of this strategy is underscored by the 38% stroke rate in this group. In contrast, in patients with intermediate or large, mobile atheroma, clinicians most often chose warfarin anticoagulation. None of these patients had recurrent stroke. Although our data are insufficient to describe the embolic risk of patients with larger atheroma who do not receive warfarin, it appears this form of anticoagulation effectively prevents stroke in these atheroma morphologies. These results suggest that mobile atheroma should be anticoagulated with warfarin and that the dimension of plaque should not be used to determine therapy.

Plaque morphology and recurrent events. Although the efficacy of therapy has not been previously described, other studies have described morphologic features of atheroma associated with recurrent events. In a prospective study of patients found to have protruding and/or mobile aortic atheroma on TEE, Tunick et al. (27) identified a 33% embolic event rate during a mean follow-up period of 13 months. In a study of 331 patients with brain infarction, the French Study of Aortic Plaques in Stroke Group (28) found that high risk plaque (≥ 4 mm thick) had a recurrent (mean follow-up 2.4 years) stroke rate of 11.9 in 100 person-years. After adjusting for confounding factors, this high risk plaque represented a relative risk of 3.8 compared with more benign-appearing plaques (< 1 mm thick). Neither of these studies describes the influence of anticoagulant therapy on the risk of recurrent embolic events. In our study, the annual stroke risk of patients with mobile atheroma not treated with warfarin was 0.32 (32 in 100 person-years). The differences in risk identified in our patients may be due not only to therapeutic choices but also to differences in plaque morphologies. Our data are limited to patients with mobile plaque. Although not elucidated, it may be expected that the majority of patients in the aforementioned studies (27,28) did not have mobile atheroma.

Paradoxical emboli after anticoagulation. In addition to its implications regarding long-term therapy of mobile atheroma, our study challenges commonly held views on the appropriate treatment immediately after the initial embolic event. Classic clinical teaching has suggested caution in treating patients with suspected atheromatous emboli with systemic anticoagulation (29). These recommendations, however, are based on very

limited data primarily consisting of case reports (23-26). The hypothesis is that anticoagulation will result in "cholesterol" embolization and the so-called "blue toe" syndrome. Our report appears to contradict this practice and would suggest that systemic anticoagulation is certainly not contraindicated, but rather should be the treatment of choice in such patients.

References

1. Winter WJ Jr. Atheromatous emboli: a cause of cerebral infarction. *Arch Pathol Lab Med* 1957;64:137-42.
2. Tunick PA, Perez JA, Kronzon I. Protruding atheromas in the thoracic aorta and systemic embolization. *Ann Intern Med* 1991;115:423-7.
3. Karalis DG, Chandrasekaran K, Victor MF, Ross JJ, Mintz GS. Recognition and embolic potential of intraaortic atherosclerotic debris. *J Am Coll Cardiol* 1991;17:73-8.
4. Mitchell MM, Frankville DD, Weinger MB, Dittrich HC. Detection of thoracic aortic atheroma with transesophageal echocardiography in patients without symptoms of embolism. *Am Heart J* 1991;6:1768-71.
5. Tunick PA, Culliford AT, Lamparello PJ, Kronzon I. Atheromatosis of the aortic arch as an occult source of multiple systolic emboli. *Ann Intern Med* 1991;114:391-6.
6. Tunick PA, Kronzon I. The improved yield of transesophageal echocardiography over transthoracic echocardiography in patients with neurological events is largely due to the detection of aortic protruding atheromas. *Echocardiography* 1992;9:491-5.
7. Simons AJ, Carlson R, Hare CL, Obeid AI, Smulyan H. The use of transesophageal echocardiography in detecting aortic atherosclerosis in patients with embolic disease. *Am Heart J* 1992;1:224-6.
8. De Rook F, Comess KA, Albers GA, Popp RL. Transesophageal echocardiography in the evaluation of stroke. *Ann Intern Med* 1992;117:922-32.
9. Toyoda K, Yasaka M, Nagata S, Yamaguchi T. Aortogenic embolic stroke: a transesophageal echocardiographic approach. *Stroke* 1992;23:1056-61.
10. Nihoyannopoulos P, Joshi J, Athanasopoulos G, Oakley CM. Detection of atherosclerotic lesions in the aorta by transesophageal echocardiography. *Am J Cardiol* 1993;71:1208-12.
11. Albers GW, Comess KA, DeRook FA, et al. Transesophageal echocardiographic findings in stroke subtypes. *Stroke* 1994;25:23-8.
12. Nishino M, Masugata H, Yamada Y, Abe H, Hori M, Kamada T. Evaluation of thoracic aortic atherosclerosis by transesophageal echocardiography. *Am Heart J* 1994;127:336-44.
13. Shyu K, Chen J, Huand Z, et al. Role of transesophageal echocardiography in the diagnostic assessment of cardiac sources of embolism in patients with acute ischemic stroke. *Cardiology* 1994;85:53-60.
14. Amarenco P, Cohen A, Tzourio C, et al. Atherosclerotic disease of the aortic arch and the risk of ischemic stroke. *N Engl J Med* 1994;331:1474-9.
15. DiTullio M, Sacco R, Kargman D, et al. Aortic arch atheromas as a risk factor for cryptogenic stroke [abstract]. *J Am Coll Cardiol* 1994;1 Suppl: 145A.
16. Mitusch R, Stierle U, Tepe C, Kummer-Klowess D, Kessler C, Sheikhzadeh A. Systemic embolism in aortic arch atheromatosis. *Eur Heart J* 1994;15: 1373-80.
17. Stone DA, Hawke MW, LaMonte M, et al. Ulcerated atherosclerotic plaques in the thoracic aorta are associated with cryptogenic stroke: a multiplane transesophageal echocardiographic study. *Am Heart J* 1995;130: 105-8.
18. Jones EF, Kalman JM, Calafiore P, Tonkin AM, Donnan GA. Proximal aortic atheroma: an independent risk factor for cerebral ischemia. *Stroke* 1995;26:218-22.
19. Khatibzadeh M, Mitusch R, Stierle U, Gromoll B, Sheikhzadeh A. Aortic atherosclerotic plaques as a source of systemic embolism. *J Am Coll Cardiol* 1996;27:664-9.
20. Gore I, Collins DP. Spontaneous atheromatous embolization: review of the literature and a report of 16 additional cases. *Am J Clin Pathol* 1960;33: 416-26.
21. Sturgill BC, Netsky MG. Cerebral infarction by atheromatous emboli. *Arch Pathol Lab Med* 1963;76:189-96.
22. Amarenco P, Duychaerts C, Tzourio C, Henin D, Bousser M, Hauw JJ. The prevalence of ulcerated plaques in the aortic arch in patients with stroke. *N Engl J Med* 1992;326:221-5.
23. Feder W, Auerbach R. "Purple toes": an uncommon sequela of oral coumarin drug therapy. *Ann Intern Med* 1961;55:911-7.
24. Bruns FJ, Segel DP, Adler S. Case report, control of cholesterol embolization by discontinuation of anticoagulant therapy. *Am J Med Sci* 1978;1: 105-8.
25. Hollier LH, Kazmier FJ, Ochsner J, Bowen JC, Procter CD. "Shaggy" aorta syndrome with atheromatous embolization to visceral vessels. *Ann Vasc Surg* 1991;5:439-44.
26. Hilton TC, Menke D, Blackshear JL. Variable effect of anticoagulation in the treatment of severe protruding atherosclerotic aortic debris. *Am Heart J* 1994;127:1645-7.
27. Tunick PA, Rosenzweig BP, Katz ES, Freedberg RS, Perez JL, Kronzon I. High risk for vascular events in patients with protruding aortic atheromas: a prospective study. *J Am Coll Cardiol* 1994;23:1085-90.
28. The French Study of Aortic Plaques in Stroke Group. Atherosclerotic disease of the aortic arch as a risk factor for recurrent ischemic stroke. *N Engl J Med* 1996;334:1216-21.
29. Bologna J, Braverman IM. Skin manifestations of internal disease. In: Isselbacher KJ, Braunwald E, Wilson JD, Martin JB, Fauci AS, Kasper DL, editors. *Harrison's Principles of Internal Medicine*, 13th ed. New York: McGraw-Hill, 1994:305.

Mobile aortic atheroma and systemic emboli: efficacy of anticoagulation and influence of plaque morphology on recurrent stroke

FA Dressler, WR Craig, R Castello, and AJ Labovitz
J. Am. Coll. Cardiol. 1998;31;134-138

This information is current as of February 10, 2012

Citations	This article has been cited by 43 HighWire-hosted articles: http://content.onlinejacc.org#otherarticles
Rights & Permissions	Information about reproducing this article in parts (figures, tables) or in its entirety can be found online at: http://content.onlinejacc.org/misc/permissions.dtl
Reprints	Information about ordering reprints can be found online: http://content.onlinejacc.org/misc/reprints.dtl